

Horse Health Leg Injuries: Third in a Four-Part Series

Diagnostic Tools

by Nancy S. Loving, DVM

Movement evaluation

To properly evaluate the degree and nature of a lameness problem, the gait can be analyzed by moving the horse both in hand and on a longe line. The person leading the horse in hand at the trot should allow the horse's head freedom to move by giving two to three feet of slack on the lead line. The horse is worked on firm, level footing when possible. The gait also can be evaluated on grass or sand, and on an area with a slight slope. Certain terrain conditions may worsen a lameness, adding to your information-gathering process. The horse can be observed with a rider up so as to factor in the significance of added weight.

A hard-pack surface with good traction gives your horse confidence so he strides out freely. A hard surface also allows one to listen to the hoof beats to audibly detect an irregular rhythm. If the surface is too slippery, a horse may be tentative and guarded in its movements on the longe line. If the ground is too rocky or rutted, an otherwise normal horse may be tentative due to transient foot soreness created by sharp stones, cobbles, or dirt clods. On a straight line trot, is there an abnormal twisting or rotation in a leg? Do the feet land squarely side-to-side?

The horse is longed in circles in

both directions to try to identify which leg or legs are involved. (See *Which Leg is Lame* below.) The horse should be longed in a 20 to 40 foot radius circle, asked for a steady trot. The trot is the preferred gait for lameness evaluation as the diagonal limbs hit the ground at approximately the same time enabling us to see and hear an aberration in this two-beat gait. A horse with a pronounced lameness is lame even at the walk (Grade 4), and should not be subjected to rigorous longeing.

Gait analysis

Some things we are looking for in the gait analysis include:

- Is there a pronounced head bob or dip as the lame limb hits the ground?
- Is the lameness intermittent or difficult to observe except under specialized conditions like circles, an incline, or a hard-pack surface (Grade 1)? Is the lameness consistently visible on a circle but not on a straight line (Grade 2)? Is the lameness visible on a straight line trot (Grade 3)?
- Does an inclined surface affect the gait? Does an uphill or downhill worsen the lameness? Does a rider's weight worsen the lameness?
- Is the degree of lameness worse in one circle direction than the other?

- Is the lameness worse on hard ground or in deep footing? (Foot or bone problems often worsen on hard ground, while tendon, ligament, or muscle injuries worsen in deep going or on inclined surfaces.)
- Does the horse protect the lame leg during the loading phase of full weight-bearing, or while the limb is swinging in motion, or both? (A supporting limb lameness often results from pain in the feet, bones, joints, or collateral ligaments. A swinging limb lameness results from injury to muscles, tendons, joint capsules, or bursal structures.)
- Does the foot land with a normal heel strike first pattern, or does the horse land flat-footed or toe first? Does the horse rock onto one side of the foot more than the other? (An abnormal foot strike hints at a painful area the horse is trying to relieve of pressure.)
- Does the horse advance the leg completely with the lame limb, or is the stride shortened?
- Does the horse have difficulty with transitions (from trot to walk, canter to trot, trot to canter, etc.)?

Which leg is lame?

Because diagonal front and rear legs strike together at the trot, it may be difficult for you to determine if a left



front or right rear, or both, is lame on cursory inspection. Use of circles in both directions helps make this determination. Carefully observe reach of each limb, flight and placement of each limb, foot landing, and the total body posture as your horse moves.

As the lame leg hits the ground, the horse guards against the pain by lifting its weight off that limb as much as possible relative to the degree of pain. As an example, if the lame leg is a front leg, then the horse's head and neck will seemingly lift above a neutral position as the sore front bears weight. As the sound leg impacts the ground, the horse's head will drop as that limb assumes the horse's full load. Sometimes the head bob is very mild, and the horse simply seems to land harder on one leg than the other. Or, it appears he shortens the time he spends loading the lame leg; the lame leg quickly departs from the ground, or advances less far than the sound leg.

If the lameness is in a rear leg, then usually the hip of the affected limb will rise or remain higher than that of the opposite good rear leg. This hip "hike" results from the horse's attempt to quickly relieve its load on the lame rear leg at the end of the stride as it assumes weight-bearing. The head and neck do not rise past the neutral position, but will drop as the lame rear leg bears weight. A rear limb lameness resulting from pain during the swinging stride phase may give the impression of a dropping of the buttocks on the affected side. This often accompanies a hip or croup injury.

Listening to the foot falls aids in diagnosis: A lame leg hits more softly as the horse tries to remove weight off

that leg. Impact of the good leg sounds louder as the horse assumes full load on the uninjured limb.

Conformation

It is important to "observe the forest through the trees," viewing the whole horse. Sometimes, conformation plays a key role in predisposing a horse to lameness. The horse should be squared up on a level, firm surface for inspection of conformation and foot placement. As an example, a horse that toes out may wing with the foot in flight, inflicting an interference injury on the inside of the opposite front leg. Additionally, the limb deviation places greater stress on the inside joints and ligaments of the crooked leg. Careful palpation can identify areas of pain. During the structural evaluation, muscle groups are compared one side to the other to detect muscle atrophy or asymmetry that might signal a chronic problem.

The horse's stance and body posture also reveal information. Is there an impression of pain or discomfort? Does the horse tend to rest a leg in a particularly odd position, point a foot, or to shift weight from limb to limb?

Feet

A systematic exam of all limb structures helps shed light on location of the problem. This exam begins at the foot and works upwards. Each foot is examined to determine if they are level and balanced, if they are symmetrical in size, and if they land squarely side-to-side with each step. Alignment of the hoof-pastern axis is carefully assessed to determine if the toes and heels are of appropriate length and

angle for your horse's conformation. The naked eye often can see significant abnormalities in foot placement, but a video camera and slow motion playback reveal other subtle problems that need to be addressed with appropriate shoeing.

The shoes are evaluated as to how appropriate they are in size and shape to support the feet. The bottom of the shoe and nail heads are inspected for wear patterns. Areas of excess wear hint at imbalances in foot landing. Flares on one side of the hoof and steep walls on the other side also chronicle uneven limb impact over time. Symmetry of each coronary band and of the heel bulbs reflect optimal internal stress absorption by the foot. Such visual clues shed light not only on potential areas of concern, but also point to therapeutic possibilities. The digital pulses in the arteries that run just behind and above the fetlock joints are evaluated for intensity. A bounding pulse may indicate inflammation within a foot.

Hoof testers squeezed across specific points on the foot often elicit a withdrawal response if a painful spot is pinched. Heel bulbs are probed for pain.

Hands-on palpation

Experienced fingers catalog nicks, scars, enlargements or puffiness over bones or joints, soft or firm swellings, painful regions of ligaments or tendons. Joints are rotated gently, and flexed and extended to check range of motion and the horse's response to these manipulations. Each limb is fully extended forward and back.

more →



Leg Injuries *continued*

Each leg is stretched forward toward the inside of the body and then gently pulled outward directly from the body with the knee or hock bent. Each leg is compared to the similar leg on the opposite side, as some horses flinch more from mental suspicion than actual pain.

Palpation of muscles with gentle, but firm and deep pressure might identify muscle strain or ligament pain at attachment points over bone. It is not uncommon for accessory muscles to become sore as the horse protects a lame leg and compensates for the added load in another part of its body. The back is a common place to see compensatory soreness particularly as a result of a hind-leg lameness.

Flexion tests

Although the feet are statistically the greatest source of injury in a majority of equine lameness problems, the joints of an equine athlete experience “wear and tear” with time. One means of detecting if lameness is related to joint pain is to perform flexion tests.

The joint or joints in question are held in a flexed position under a constant pressure for approximately 1-2 minutes. Then the limb is released and the horse is immediately asked to trot off in a straight line for about 60 feet, and back. The first few steps reveal the most information, so the runner should concentrate on urging the horse to follow immediately at the signal to go.

Placing a joint under tension with a flexion test increases pressure in the bones, in the synovial lining of the joint, and in the joint capsule. If there is no inflammation in the joint or surrounding support structures of the joint, the horse trots off sound. An inflamed joint has a low threshold for pain so a horse often resents crimping of an injured joint. A painful joint varies in its response, anything from several steps of lameness to a complete reluctance to weight-bear on the limb as the horse is trotted out.

In some cases, pain does not stem from inflammation within the joint itself, but may arise from a muscle, tendon, or ligament that is stretched in the

process of the flexion test. If the horse tests positive (lame) due to a flexion of the entire limb, then the next step is to isolate each component part of the leg. The flexion test is repeated for each area in a process of elimination.

In the front leg, the elbow and shoulder flex together, the carpus (knee) can be flexed separately, and the lower joints (fetlock, pastern and coffin joints) all flex simultaneously. In many horses, it is possible to isolate the fetlock joint in its own flexion test. In the rear leg, hock, stifle and hip joints are all flexed together. The stifle and hip can be flexed separately, while the lower joints (fetlock, pastern and coffin) flex as in the front limb.

Through a careful and tedious process, the offending joint soreness may be isolated to a specific region of the leg. Often joint inflammation is accompanied by puffiness of the joint capsule (an increased volume of synovial fluid), by a reduced range of motion of the joint, by a thickened joint capsule, and/or heat around the joint. However, many times radiographs are necessary to see chronic joint problems.

Diagnostic nerve blocks and interpretation

Often during a lameness exam, many musculoskeletal structures can be eliminated as a source of the lameness, but your veterinarian may still remain perplexed as to the exact source. Suppose the horse has been examined in motion, on various surfaces, legs have been palpated, manipulated, and examined in minute detail, the feet have been carefully assessed and hoof tested, and flexion tests did not yield any definitive information. Your horse still hurts, and a complete physical exam has yielded no definite answer. So what happens now?

Provided the horse is exhibiting at least a Grade 2 lameness (lame steps are consistently visible on a circle), the next step involves a systematic infiltration of local anesthetic (similar to novacaine) into nerve branches of the lame leg. This procedure, called a *diagnostic nerve block*, facilitates a more specific identification of the pain source. Starting from the bottom of the leg, and working upwards, regional

areas of the limb are numbered. For starters, the initial nerve block (of the *palmar digital nerves*) results in loss of sensation to the back third of the foot. Multiple structures are desensitized with the P-D (palmar digital) block. Not only is the navicular apparatus (the navicular bone, the navicular bursa, and the deep digital flexor tendon running across the navicular bone) numbed, but so are the digital cushion, the frog, the sole, the bars, the back third of the coronary band and hoof, and the heels. An injury to any one of these structures results in a horse with heel soreness.

If the horse goes entirely sound with the P-D block, then x-ray films can be taken focusing on structures within the rear third of the foot. If the horse improves somewhat with a P-D block, but not entirely, another ailment may coexist with a heel soreness problem.

Then, from the ground up, your vet continues the diagnostic nerve blocks up the limb in a process of elimination. For example, the next step is to numb the entire foot by infiltrating anesthesia in a ring around the pastern, or directly over two nerve branches that run along the bottom and backside of the fetlock. Everything below the point of anesthesia will be numb and free of pain, while every structure above that point retains full sensation.

If a specific joint is implicated as a source of lameness based on heat, swelling, poor range of movement, or a positive flexion test response, local anesthetic can be injected directly into an individual joint. If the horse goes sound with a joint block, then radiographic evaluation may reveal degenerative joint disease, or allude to soft tissue inflammation within or around the joint by ruling out actual degenerative joint changes.

Other diagnostic tests

Sophisticated equipment is also available for our performance horses to look as deeply as necessary for the source of a problem. Once a problem joint or bone has been isolated, x-ray films (**radiographs**) can be taken to analyze the health of bone, and to look for reaction around bone or a joint that indicates ligament tearing, joint cap-

sule tearing, degenerative arthritis, or a stress fracture. If the lameness exam reveals concern about a tendon or ligament, an **ultrasound** exam is a non-invasive method of "imaging" the internal components of tendon or ligament fibers. The extent of the damage can be visualized, and your vet can then outline an appropriate therapeutic course of treatment and estimate a prognosis for return to soundness. It has been shown that the presence or absence of overt clinical signs (such as pain, heat, swelling, or lameness) correlate poorly with the severity of a tendon injury. The only accurate method of assessment is with ultrasound. To track healing progress, ultrasound exams are repeated at 2-3 month intervals.

Another non-invasive diagnostic technique known as **thermography** uses an infrared scanner to identify areas of tissue inflammation by separating "cold" non-inflamed tissue from "hot" injured tissue. The specific location of the injury is visualized as "hot spots" of different color or intensity on a video screen. The image created translates to temperature gradients of

the skin surface that reflect temperature differences in underlying tissue or bone.

If a mysterious lameness continues to elude your veterinarian's diagnostic powers, a visit to a University Teaching Hospital or private referral practice may shed more light by the use of **nuclear scintigraphy**. A radioisotope is injected into the horse's bloodstream, and a specialized gamma camera and computer read the radioactive intensity as the isotope localizes in areas of increased blood flow due to inflammation. Nuclear scintigraphy picks up "hot spots" anywhere in the body, particularly in bone and joints.

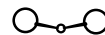
Examining the sound horse

To give you the best opportunity to help your horse when a problem arises, make a special point of having your vet do a "lameness exam" before an injury develops, when you feel your horse is moving at its best. It is extremely helpful to be able to compare a mild gait irregularity with a mental picture of how your horse normally moves. Not all horses travel perfectly soundly due

to differences in muscle strength and balance from side-to-side.

At the very least, get out your video camera and make a tape of your horse moving freely in the pasture or paddock, on the longe line, and under saddle. Stand in front of your horse and to the side, and film him as he is led back and forth at both a walk and a trot. Video tapes taken at several month intervals give you a baseline to which you can refer in the future.

To correctly identify a lameness and to outline an appropriate course of treatment, the entire horse should be thoroughly evaluated by a veterinarian as soon as you detect something wrong. It is not unusual for a horse to experience two or more musculo-skeletal problems simultaneously, one influencing the other or one eliciting the other. Successful therapy depends on a complete and accurate diagnosis. The more quickly the problem is identified, the greater the opportunity to implement immediate treatment that can hasten recovery.



ADDRESS CHANGE

Please allow 45 days for address change

*Paste old address area from current issue of
The Trail Less Traveled
here.*

NEW ADDRESS

NAME _____

ADDRESS _____

CITY _____

STATE/ZIP _____

PHONE _____

(SO WE MAY CALL IF CONFIRMATION IS NECESSARY)

MAIL TO: CIRCULATION DEPARTMENT
THE TRAIL LESS TRAVELED
730 FRONT ST., LOUISVILLE, CO 80027

Diamond Wool 3 Pocket Problem Solver Pad



100% Wool Felt
Canvas Top w/ Inserts

- Sore Spot?
-Cut a hole in the proper insert
- Saddle tree bridges?
-Remove the front & rear inserts
- Qtr. Horse tree on a mule?
-Remove center insert

Only \$54.95 + s/h



Brighton Feed & Saddlery

370 N Main Street • Brighton, CO
303-659-0721 or 800-237-0721
www.brightonsaddlery.com